

A Cross-sectional Descriptive Study of Dermoscopy in various Nail Diseases at a Tertiary Care Center

¹Dipali Rathod, ²Meena Bhaskar Makhecha, ³Manas Chatterjee, ⁴Tishya Singh, ⁵Shekhar Neema

ABSTRACT

Introduction: Nail diseases may often possess a challenge for the treating dermatologist, as they may primarily be affected without any skin involvement and sometimes may present with subtle changes which can be easily missed by the naked eye. The macroscopic nail changes can be assessed very well with a naked eye, however, the important minutiae may be assessed with a dermoscope.

Aim: To study the characteristic dermoscopic findings in various nail diseases.

Materials and methods: A total of 250 patients (males-130, females-120) with clinically evident nail diseases were enrolled in this cross-sectional descriptive study. After a thorough clinical examination, patients were subjected to dermoscopic examination of all 20 nails. Chi-square test or Fisher's exact test (in a very few patients of nail diseases) were used for statistical analysis, with a significance threshold of $p < 0.05$.

Results: Nail psoriasis ($n = 45$) was the commonest nail disease found in which the most common dermoscopic feature was circular punctate depressions (64.5%). Onychomycosis ($n = 40$) was the next common disease in which yellowish discoloration (100%) was commonly seen in all patients and rough scaly surface (100%) in the total dystrophic type. In pitted keratolysis ($n = 19$) transverse brown bands (57.9%) were most commonly seen as was the case in eczemas. Lichen planus ($n = 14$) was associated with longitudinal fissuring (64.3%) most commonly. Trachyonychia ($n = 5$) was associated with longitudinal fissuring (100%) in all cases. The most common dermoscopic feature of alopecia areata ($n = 4$) was circular punctate depressions (75%). Systemic scleroderma ($n = 4$) typically showed giant capillaries (75%) as the most common feature.

Conclusion: A meticulous search with the dermoscope, furnishes minuscule details of the nail unit that can be diagnostic of several nail diseases at an early stage before dystrophy sets in. However, further studies are required to validate these findings.

Clinical significance: Dermoscopy is a noninvasive complementary tool which aids in diagnosis of nail diseases more quickly and can also be used for monitoring the evolution, therapeutic response, and prognosis of these diseases.

Keywords: Alopecia areata, Lichen planus, Melanonychia, Nail dermoscopy, Nail psoriasis, Onychomycosis, Pitted keratolysis, Scleroderma, Trachyonychia.

How to cite this article: Rathod D, Makhecha MB, Chatterjee M, Singh T, Neema S. A Cross-sectional Descriptive Study of Dermoscopy in various Nail Diseases at a Tertiary Care Center. *Int J Dermoscopy* 2017;1(1):11-19.

Source of support: Nil

Conflict of interest: None

INTRODUCTION

Nails may be involved primarily or secondarily due to underlying systemic diseases and their examination may provide clues to establish the diagnosis and guidance regarding the management of these nail diseases. Several skin, hair, and nail diseases may result in severe nail abnormalities, which if not addressed, may cause functional interference and permanent dystrophy. Diseases of nail comprise approximately 10% of all the dermatological conditions.^{1,2} Clinicopathologic tools are time-consuming and give false negative results in up to 35% of patients. Although, the naked eye can appreciate majority of the macroscopic details of the nail unit apparatus, dermoscope furnishes details which may be easily missed. This article provides the diagnostic importance of dermoscope in the evaluation of various nail diseases.

However, before we move onto the main topic, let us see the difference between nail and skin dermoscopy.

Nail dermoscopy is technically difficult owing to nail size, shape, convexity, and hardness. The entire nail cannot be visualized as a whole at one particular time, therefore, cannot be easily interpreted and it is cumbersome to take pictures of this area. Nail plate surface changes can be appreciated with dry dermoscopy, whereas color abnormalities can be appreciated with large quantities of interface medium (linkage fluid gel) or by use of polarized dermoscopy.

Normal Nail Unit under the Dermoscope

The nail plate appears pale pink in color with smooth and shiny surface. Nail bed below the transparent plate

^{1,2,5}Assistant Professor, ³Senior Advisor and Head, ⁴Resident

^{1,3}Department of Dermatology, INHS, Asvini, RC Church, Colaba Mumbai, Maharashtra, India

^{2,4}Department of Dermatology, Hinduhrudaysamrat Balasaheb Thackeray Medical College & Dr. Rustam Narsi Cooper Municipal General Hospital, Juhu, Vile Parle (West), Mumbai, Maharashtra India

⁵Department of Dermatology, Command Hospital (EC), Kolkata West Bengal, India

Corresponding Author: Dipali Rathod, Assistant Professor Department of Dermatology, INHS, Asvini, RC Church, Colaba Mumbai, Maharashtra, India, Phone: +918655638949, e-mail: email2dipali@yahoo.co.in

appears pale pink too. The epithelium of proximal nailfold (PNF) has a smooth surface with pale pink to brown color. Cuticle is easily visible as a transparent transverse band that seals the nail plate to PNF. Hyponychial epithelium shows digital creases and capillaries of the dermis appear as red dots (40× magnification).

AIM

Our aim was to study the characteristic dermoscopic findings in various nail diseases.

MATERIALS AND METHODS

After obtaining the approval of institutional ethics committee, a total of 250 consecutive patients were enrolled in the study after written informed consent. Ours was a cross-sectional descriptive study conducted over a period of 8 months (October 2014 - May 2015).

Patients with clinically detectable nail unit involvement and belonging to all age groups of both sexes were included whereas those already on treatment for the primary cause and those not wilfully giving consent were excluded. The diagnosis was established by two senior consultants, based predominantly on the clinical features.

Each patient was subjected to a detailed history regarding demographic profile, onset and evolution of the nail changes, history pertaining to associated skin, and systemic complaints. This was followed by a complete general physical examination and cutaneous and systemic examination. Later, dermoscopic evaluation of all the nails was done using a handheld polarized Heine's Delta 20 dermoscope whereas digital dermoscopic images were taken with a Canon 1200D DSLR camera. Ultrasound gel was used as the linkage fluid between the contact plate and the nail plate.

Statistical Methods used for Analysis

After data collection, it was entered in Microsoft Excel and analyzed using STATA version 13. The quantitative data was presented with the help of mean, standard deviation, median, and interquartile range and the qualitative data was presented with the help of frequency and percentage tables.

We calculated the means and standard deviations for the linear variables and proportions for the categorical variables. The proportions across various categories were compared using the Chi-square test or the Fisher's exact test (in those conditions where a very few patients were there in the sample). A p-value of less than 0.05 was considered to be statistically significant.

RESULTS

After enrolling the patients, the data were collected, tabulated, analyzed, and the results obtained were as follows:

A total of 250 out of 42,105 patients attending dermatology OPD were enrolled, that accounted for an incidence of 0.60% during this study period.

The mean age was 37.8 years. The highest number (49) of patients belonged to the age group 31 to 40 years (19.6%) and the lowest number of patients (6) belonged to the age group >70 years (2.4%). The youngest patient was 3-year-old and the oldest was 72-year-old.

Among 250 patients, 130 (52%) were males and 120 (48%) were females and M : F ratio was 1.09 : 1.

Right hand fingernails were most commonly involved in 192 patients (78.6%) followed by left hand fingernails in 171 patients (68.4%), right foot toenails in 109 (43.6%) and left foot toenails in 102 (40.8%). The finger nails were significantly more commonly involved as compared with the toe nails ($p = 0.000$).

A total of 140 patients (56%) presented with onset of disease ranging from 1 month to 1 year. However, the shortest duration observed was 1 week and longest duration was 20 years.

The most common occupations observed were housewives 77 (30.8%) followed by students 58 (23.2%), domestic helps 40 (16%), and laborers 29 (11.6%).

Among 80 patients (32%) with systemic diseases, the most commonly observed conditions were diabetes mellitus in 30 patients (34.5%) followed by hypertension in 29 patients (33.3%) and ischemic heart disease in 5 patients (5.7%). Both, underlying dermatological disease (Table 1) and nail changes (Table 2) were encountered in 181 patients (72.4%), while nail disease alone was observed in 69 patients (27.6%).

Statistically significant dermoscopic nail findings of the common nail diseases observed in our study were as follows:

Nail Psoriasis (n = 45)

More common - circular punctate depressions (64.5 vs 5.9%, $p = 0.000$) (wherein 64.5% stands for percentage of this dermoscopic manifestation seen in nail psoriasis and 5.9%, that of this manifestation seen in other nail diseases), reddish pink border (62.3 vs 1%, $p = 0.000$), brown-purple streaks (48.9 vs 21.5%, $p = 0.000$), white color (35.6 vs 2%, $p = 0.000$), nail free edge nonruinous aspect (35.6 vs 3.5%, $p = 0.000$), irregular edge (33.4 vs 2%, $p = 0.000$), dilated capillaries (31.2 vs 1%, $p = 0.000$), linear edge (17.8 vs 5.4%, $p = 0.010$), proximal nail scaling (17.8 vs 2%, $p = 0.000$), and orange pink spot (11.2 vs 0%, $p = 0.000$).

Less common - brown color (4.5 vs 25.9%, $p = 0.001$), gray black color (2.3 vs 19.6%, $p = 0.003$), and rough scaly surface (2.3 vs 11.8%, $p = 0.057$ %).

Table 1: Dermatological diseases

Sl. no.	Dermatological diseases	Frequency	Percentage
1	Psoriasis vulgaris	46	25.4
2	Eczema	24	13.2
3	Pitted keratolysis	19	10.5
4	Tinea	17	9.4
5	Lichen planus	15	8.3
6	Verruca vulgaris	15	8.3
7	Candidiasis	7	3.8
8	Alopecia areata	5	2.7
9	Systemic scleroderma	4	2.2
10	Urticaria	3	1.7
11	Hansen's disease	3	1.7
12	Prurigo simplex	3	1.7
13	Lichen simplex chronicus	3	1.7
14	Vitiligo	2	1.2
15	Vitiligo and psoriasis	2	1.2
16	Erythroderma	2	1.2
17	Epidermolysis bullosa	2	1.2
18	Neurofibromatosis	1	0.5
19	Dariers disease	1	0.5
20	Laugier Hunziker syndrome	1	0.5
21	Acne vulgaris	1	0.5
22	Systemic lupus erythematosus	1	0.5
23	Tuberous sclerosis	1	0.5
24	Nutritional dermatoses	1	0.5
25	Juvenile plantar dermatoses	1	0.5
26	Ectodermal dysplasia	1	0.5
Total		181	100

Table 2: Various nail diseases

Sl. no.	Nail diseases	Frequency	Percentage
1	Nail psoriasis	45	18
2	Onychomycosis	40	16
3	Chronic paronychia	24	9.6
4	Periungual verrucae	22	8.8
5	Nails in pitted keratolysis	19	7.6
6	Nails in eczema	19	7.6
7	Nail lichen planus	14	5.6
8	Longitudinal melanonychia	12	4.8
9	Ingrown toenail	7	2.8
10	Trachyonychia	5	2
11	Subungual hematoma	5	2
12	Nails in alopecia areata	4	1.6
13	Acute paronychia	4	1.6
14	Nails in systemic scleroderma	4	1.6
15	Exogenous nail discoloration	4	1.6
16	Nail in Hansen's disease	3	1.2
17	Leukonychia	3	1.2
18	Traumatic onycholysis	2	0.8
19	Nails in erythroderma	2	0.8
20	Nails in epidermolysis bullosa	2	0.8
21	Platonychia	2	0.8
22	Twenty nail dystrophy	2	0.8
23	Nails in systemic lupus erythematosus	1	0.4
24	Nails in vitiligo and psoriasis	1	0.4
25	Nails in dariers disease	1	0.4
26	Nails in tuberous sclerosis	1	0.4
27	Onychomadesis	1	0.4
28.	Nails in ectodermal dysplasia	1	0.4
Total		250	100

Onychomycosis (n = 40)

Distal Lateral Subungual Onychomycosis (DLSO)

More common - yellowish-white color (100 vs 18.1%, p = 0.000), longitudinal striae of different colors (73.9 vs 0%, p = 0.000), nail free edge with ruinous aspect (73.9 vs 0%, p = 0.000), jagged edge with spikes (60.9 vs 1.8%, p = 0.000), white blotches (43.5 vs 12.4%, p = 0.001), and rough scaly surface (34.8 vs 7.5%, p = 0.001).

Less common - transverse brown bands (4.4 vs 27.3%, p = 0.012).

Total Dystrophic Onychomycosis (TDO)

Rough scaly surface (100 vs 3.9%, p = 0.000), blackish brown spots/globules/streaks (93.8 vs 22.7%, p = 0.000), yellow color (75 vs 22.3%, p = 0.000), and white blotches (37.5 vs 13.7%, p = 0.021).

Chronic Paronychia (n = 24)

Transverse brown bands (87.5 vs 18.6%, p = 0.000), brown color (66.7 vs 17.3%, p = 0.000).

Periungual Verrucae (n = 22)

Blackish brown spots/globules/streaks (100 vs 20.2%, p = 0.000).

Nails in Pitted Keratolysis (n = 19)

Transverse brown bands (57.9 vs 22.6%, p = 0.001), reddish pink/brown streaks (52.7 vs 24.3%, p = 0.007), gray black color (47.4 vs 13.9%, p = 0.000), and brown color (42.2 vs 20.4%, p = 0.028).

Nails in Eczema (n = 19)

Transverse brown band (73.7 vs 21.3%, p = 0.000), brown color (42.2 vs 20.4%, p = 0.028).

Nail Lichen Planus (n=14)

Longitudinal fissures (64.3 vs 5%, p = 0.000), white dots and streaks (57.2 vs 11%, p = 0.000), lamellar splitting (28.6 vs 3.4%, p = 0.002), fragmented/loss of nail plate (28.6 vs 0.9%, p = 0.000), and longitudinal grooves converge to center (21.5 vs 0%, p = 0.000).

Longitudinal Melanonychia (n = 12)

Regular parallel gray lines (75 vs 13.5%, p = 0.000), regular parallel brown lines (25 vs 2.1%, p = 0.004).

Ingrown toenail (n = 7)

Dilated and broken capillaries (42.9 vs 1.3%, $p = 0.000$), whitish discoloration with brown necrotic areas (42.9 vs 1.3%, $p = 0.000$).

Trachyonychia (n = 5)

Longitudinal fissures (100 vs 6.6%, $p = 0.000$), white dots and streaks (80 vs 12.3%, $p = 0.001$).

Subungual Hematoma (n = 5)

Dark red-black color (80 vs 0.5%, $p = 0.000$), rounded proximal border (80 vs 0%, $p = 0.000$), distal border longitudinal lines (80 vs 0%, $p = 0.000$), and red purple color (20 vs 0%, $p = 0.020$).

Alopecia Areata (AA) (n = 4)

Circular punctate depressions (75 vs 15.5%, $p = 0.015$), longitudinal fissures (50 vs 7.8%, $p = 0.036$).

Systemic Scleroderma (n = 4)

Proximal nailfold - showing giant capillaries (75 vs 0.5%, $p = 0.000$), loss of capillaries (75 vs 0%, $p = 0.000$), capillary architectural disorganization (75 vs 0%, $p = 0.000$), ramified/bushy capillaries (75 vs 0%, $p = 0.000$), and brown necrotic areas (50 vs 1.7%, $p = 0.003$).

DISCUSSION

According to the results obtained in our study, nail diseases were commonly observed in the 4th decade [49(19.6%)], followed by 2nd decade [47(18.8%)]. This could be attributed to the fact that people in this age group are more conscious about cosmetic aspects of their nails and keep an approachable tendency toward health care services. This was in discordance with observations reported by Neerja et al.³ where majority [200(40%)] belonged to 3rd and 4th decade, followed by 5th and 6th decade [150(30%)].

The male preponderance in our study may be associated with the relatively increasing cosmetic concern among them and easy access to medical services. Similar observations were reported by Neerja et al.³

The higher incidence among housewives and domestic helps can be attributed to their frequent contact with water, exposure to irritants and repeated trauma. They commonly developed chronic paronychia (15.4%) and nail changes due to pitted keratolysis (15.4%), followed by DLSO (11.1%). Similar findings were reported by Neerja et al;³ however, in addition we found that students (23.2%) were commonly affected owing to the increased awareness about nail diseases.

The duration of nail changes at the time of presentation was highly variable (1 week to 20 years). The relative asymptomatic nature of the disease may have contributed to this long duration.

Psoriasis is probably the most common dermatological disorder affecting the nails and is seen in 10 to 78% of psoriatic patients,⁴⁻⁶ whereas isolated nail involvement is seen in only 5 to 10%.⁷ Similar findings were observed by Neerja et al.³ The nail changes in psoriasis are secondary to internal factors whereas in eczema, its mainly due to external factors. The increased incidence of eczema (13.2%) may be associated with the occupational exposure in housewives, domestic helps, cooks, and cement workers. Hand dermatosis is commoner in these occupations, with trauma acting as a predisposing factor.

The frequency of systemic diseases observed in our study could be probably due to the increased incidence of inappropriate diet, addictions, sedentary lifestyle, and obesity. However, HIV was the common systemic disease reported by Neerja et al.³

Nail psoriasis (18%) was the commonest nail disease observed in our study, followed by onychomycosis (16%), chronic paronychia (9.6%), and others.

However, a few dissimilarities were observed by Neerja et al,³ who found onychomycosis (25%) to be the commonest followed by psoriasis (20%), eczema (20%), paronychia (8%), and lichen planus (5%).

Recently, dermoscope has been extensively used for adnexal disorders and research has been undertaken for assessment of nail diseases. To the best of our knowledge, there have been individual studies on a few of the nail diseases; however, a very few studies have evaluated the dermoscopic features of several nail diseases. The findings of these studies have been reported without the details of demographic and clinical data; therefore, this has precluded us from comparing the results of our study with theirs.⁸⁻¹¹

In patients with nail psoriasis; clinically, pitting (64.3%) was observed most frequently, which on dermoscopy were seen as circular punctate depressions filled with gel and surrounded by a whitish halo peripherally. The pitting seen in psoriatic nails is irregular in size and distribution, deep and randomly distributed. Psoriatic onycholysis had a distinctive dermoscopic appearance of (62.3%) typical proximal reddish pink border (Fig. 1) with white (35.6%) onycholytic area distally. The onycholytic edge was irregular in 33.4% and linear in 17.8%. Salmon patch, which is also known as the "oil drop sign," was seen as orange pink spot (11.2%). Parakeratosis remains the main reason behind these manifestations. Splinter hemorrhages were appreciated as brown purple streaks (48.9%) which result from rupture of capillaries causing

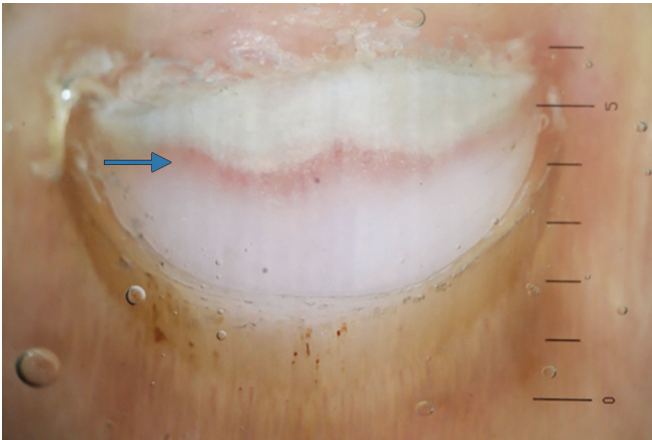


Fig. 1: Reddish pink border of onycholysis in nail psoriasis (blue arrow)




Fig. 2: Longitudinal striae of different colors of onycholytic margin in DLSO (blue arrow)

extravasation of blood within grooves beneath nail plate. These hemorrhages are bright red when fresh and darker when older.^{12,13} Subungual hyperkeratosis (35.6%) at the nail free edge seemed nondestructive (nonruinous aspect). The distal nail plate in these patients showed dilated capillaries (31.2%). Similar dermoscopic findings have been reported by Nakamura et al⁸ and Farias et al.¹¹

Iorizzo et al¹⁴ studied only the hyponychium in patients (n = 30) with nail bed psoriasis with videodermatoscope and observed dilated, tortuous, and irregularly distributed capillaries in all patients (100%) and found a positive correlation between the capillary density and psoriasis severity.

Tulika et al¹³ investigated chronic plaque psoriasis (n = 68) patients to detect signs of subclinical nail involvement, wherein only 46 patients showed dermoscopic findings. They reported coarse pits (39%), onycholysis (21.7%), splinter hemorrhages (10.8%), and oil drop sign (4.3%) as the common manifestation; however, their incidence was lower as compared with ours.

Discordant findings were reported by Yorulmaz et al¹⁵ while evaluating 67 nail psoriasis patients with videodermatoscope; wherein splinter hemorrhages (73.1%) was commonly observed followed by pitting (58.2%), distal onycholysis (55.2%), dilated hyponychial capillaries (35.8%), and pseudo-fiber sign (34.3%) [corresponding to arterial and venous ends of capillaries] and also found a positive correlation between these features and disease severity. However, pseudo-fiber sign was not appreciated in our study as our dermoscope had only 10× magnification.

Onychomycosis was the second common nail disease observed in our study. However, as opposed to the literature, we found fingernail involvement to be more common than toenails. The DLSO-23 (9.2%) was the commonest type encountered, followed by TDO 16 (6.4%) and proximal subungual onychomycosis in one case.

On dermoscopy, we observed yellowish-white discoloration of onycholytic nail in all patients (100%). Five of the DLSO patients showed secondary infection with *Pseudomonas*; giving in addition, greenish color to the onycholytic part. In patients with DLSO, onycholytic edge showed jagged edge with spikes (60.9%) proximally where the nail plate was still attached to the bed while the part of nail lifted above the bed showed (73.9%) longitudinal striae of different colors (Fig. 2), thus giving an overall appearance similar to aurora borealis ('aurora pattern').¹⁶ The jagged edge with spikes is attributed to the proximal progression of dermatophytes, whereas the discoloration reflects the color of fungal colonies. Subungual hyperkeratosis (73.9%) at the distal nail free edge seemed destructive (ruinous aspect). Beau's lines (4.4%) were seen as transverse brown bands. Piraccini et al¹⁶ retrospectively analyzed records of 37 DLSO patients who underwent videodermoscopy and observed jagged edge with spikes in all 37 patients (100%) and longitudinal striae in 32 patients (86.4%).

De Crignis et al¹⁷ studied dermoscopic findings in a total of 502 patients with nail diseases and found DLSO in 336 patients (66.93%) and commonly observed "ruin appearance" (88.09%) and longitudinal striae (79.46%).

In patients with TDO, dermoscopically, we observed retained keratin debris as rough scaly surface (100%), splinter hemorrhages and blood spots as blackish brown spots/globules/streaks (93.8%).

Periungual verrucae were seen in 22 (8.8%) patients of which six had subungual extension, with onycholysis being the commonest nail change seen in 50%. This nail change may be attributed to the abnormal cell growth which causes nails to grow abnormally, appear raised and permanently deformed. Similar findings were observed by Neerja et al³ with lower incidence (3%) and Robert et al.¹⁸ Dermoscopy showed (100%) multiple, blackish-brown spots/globules/streaks (Fig. 3) which represent

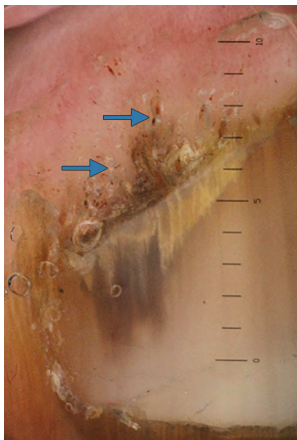


Fig. 3: Blackish brown spots (dark blue arrow) and streaks (light blue arrow) in periungual verruca

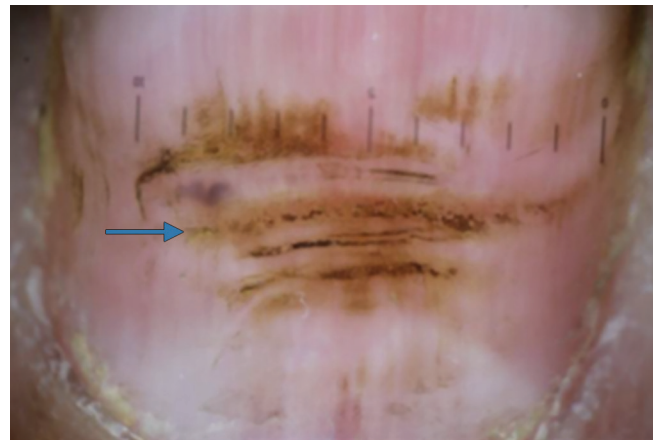


Fig. 4: Transverse brown bands in chronic paronychia (blue arrow)

the dilated capillaries of papillary dermis. Similar findings were observed by Piraccini et al.⁹

Studies on dermoscopic findings in TDO, chronic paronychia, pitted keratolysis, hand eczema, trachyonychia, AA, and traumatic onycholysis are lacking.

Chronic paronychia is inflammatory dermatoses of the nailfolds, with secondary effects on the nail matrix, nail growth, and soft tissue. It results from irritants (wet work), caustic materials, and candidal infection. On dermoscopy, multiple Beau's lines were observed as (87.5%) transverse brown bands (Fig. 4) and majority of the nails showed brownish discoloration (66.7%). Beau's line results from transient arrest in the growth of nail plate whereas brownish discoloration represents postinflammatory hyperpigmentation.

In patients with pitted keratolysis, we observed that paronychial changes corresponded to the disease duration. Acute stage showed well-defined areas of eaten-up stratum corneum with oozing, erythema, and inflammation whereas subacute stage showed scaling and edema. Chronic paronychial stage showed a keratotic PNF skin and formation of pockets between nail plate and paronychium at the corners of the nail, due to cuticle loss. The changes seen in the PNF and cuticle corresponded to degree of nail plate involvement in the form of onychodystrophy. On dermoscopy, we observed transverse brown bands (57.9%) corresponding to Beau's lines, (52.7%) nail bed capillaries/hemorrhages seen as reddish pink/brown streaks (Fig. 5) respectively, and grayish black (47.4%) and brownish (42.2%) nail discoloration secondary to the inflammatory process.

Dermoscopy of the nails affected by hand eczema showed transverse brown bands (73.7%) which were clinically consistent with Beau's lines and brownish discoloration (42.2%) which supported inflammatory process.

Trachyonychia was seen in 5 (2%) patients, predominantly children (60%). Two of them had onychorrhexis

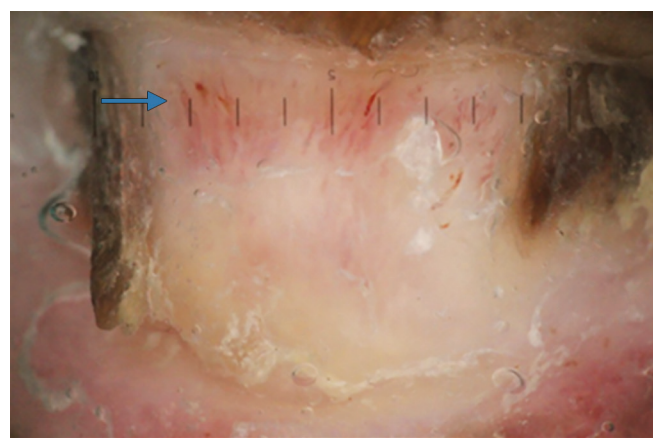


Fig. 5: Fragmented nail plate and nail bed capillaries seen as reddish pink streaks in pitted keratolysis (blue arrow)

and koilonychia of all 20 nails. However, other age groups were also affected as suggested by Gordon K et al.¹⁹ Dermoscopic examination revealed longitudinal fissures (100%) and white dots and streaks (80%) corresponding to onychorrhexis and brittle nails.

Alopecia areata was observed more commonly in children 4 (1.6%). Common dermoscopic findings observed in them were circular punctate depressions (75%) consistent with pitting and longitudinal fissures (50%) consistent with onychorrhexis. The changes in the PNF and cuticle corresponded to the above findings. The pits in AA are shallow and arranged regularly in a geometric fashion giving rise to the "Scotch Plaid" pattern.

Nail involvement of one or all the nail components occurs in 10% of patients with lichen planus.²⁰ Considering severe consequences, early diagnosis is, therefore, essential. Involvement of nails occurs most commonly in children. We observed PNF changes corresponded to degree of nail plate involvement.

Dermoscopy showed longitudinal fissures (64.3%) and (57.2%) white dots and streaks (Fig. 6) corresponding to onychorrhexis and brittle nails, fragmented nail plate/




Fig. 6: Longitudinal fissures and distal splitting with white dots and streaks in nail lichen planus (blue arrow)

loss of nail (28.6%) corresponding to onychodystrophy/anonychia, lamellar splitting (28.6%) corresponding to onychoschizia, and longitudinal grooves converge to center (21.5%) corresponding to dorsal pterygium.

In a similar study (n = 11), discordant findings were observed by Nakamura et al,²¹ wherein longitudinal streaks converging to center was commonly observed in 82.28%, chromonychia in 55.70%, fragmentation of nail in 50.63%, trachyonychia in 40.51%, and splinter hemorrhages in 35.44% patients.

In longitudinal melanonychia, color of the band indicates whether it is caused by proliferation of the melanocytes (brown-black) or activation (gray). Melanocyte activation causes include physiologic, trauma, dermatological and systemic diseases, iatrogenic, drugs, etc., whereas hyperplasia causes include lentigo, nevus, and melanoma. Majority of the melanocytes that are active (a few dormant) exist in the distal nail matrix (melanonychia generally originates here), whereas those in proximal nail matrix are predominantly dormant. Presence of pigment in the upper portion of the nail free edge confirms its origin to be in proximal matrix; whereas if in the lower portion, its origin lies in distal matrix.²² A biopsy of the lesion located in the proximal matrix would result in permanent nail dystrophy in comparison with the distal matrix biopsy. Therefore, with the help of a dermoscope, one can plan a meticulous biopsy so as to avoid the proximal nail matrix and further nail dystrophy.

We observed regular parallel gray lines (75%) and regular parallel brown lines (25%) on dermoscopy. The parallel gray lines were seen in 3 DLSSO, 3 chronic paronychia, 2 eczema and 1 psoriasis patient while the brown lines were seen in 3 patients with nail matrix nevus. Similar findings were observed by Lencastre et al¹⁰ and Ronger et al.²³

Ingrown toenail (Onychocryptosis) was seen in 7 patients (2.8%); pain was the most common complaint among them. Four had developed chronic paronychia, while granulation tissue (pyogenic granuloma) was seen at the lateral nailfolds in only 3 patients. Dermoscopy of the friable red papulonodule (granuloma) showed dilated and broken capillaries (42.9%) and whitish discoloration with brown necrotic areas (42.9%). These findings were similar to those observed by Piraccini et al.⁹

Subungual hematoma develops due to extravasation of blood beneath the nail plate following trauma which may involve entire or part of the nail. A total of seven patients (2.8%) presented with changes following trauma, however only five confirmed history of trauma to nails. Toe nails were affected commonly as compared to fingernails. Subungual hematoma 5(2%) and onycholysis 2(0.8%) were commonly appreciated in them. Recent hematoma is seen as red purple color with irregular margins whereas older one is roundish and darker. Dermoscopy of subungual hematoma commonly showed dark red black color (80%) with rounded proximal border (80%), distal border with longitudinal lines (80%), and red purple color (20%). Similar findings were observed by Piraccini et al⁹ and Lencastre et al.¹⁰ Traumatic onycholysis on dermoscopy showed regular and smooth line of detachment surrounded by pink bed and black spots (0.8%) and splinter hemorrhages as brown purple streaks (0.8%).

In systemic sclerosis (SSc) patients 4 (1.6%), the entire nail could be dermoscopically visualized because of variations in the nail plate, such as micronychia, parrot beak nails, and onychia. Dermoscopic findings commonly observed were PNF showing giant capillaries (75%), loss of capillaries (75%), capillary architectural disorganization (75%), ramified/bushy capillaries (75%), and brown necrotic areas (50%) consistent with hemorrhages. Similar findings were observed by Lencastre et al¹⁰ and Dogan et al.²⁴ In addition, Dogan et al found dermoscopy a more efficient, easily applicable, and convenient method than videocapillaroscopy (VCAP) in identifying pathognomonic nailfold changes in SSc; however, VCAP facilitates a more detailed evaluation.²⁴ Ohtsuka evaluated 62 patients of SSc with dermoscope and found higher incidence of dilated capillaries (43.5%), avascular areas (25.8%), and nailfold bleeding (12.9%).²⁵

Similar patterns may be found in patients with other connective tissue diseases (eg., dermatomyositis, SLE, and MTCD). In primary Raynaud's phenomenon, capillaroscopy is normal, however, those associated with connective tissue disease show capillaroscopic alterations.²⁶ Progressive loss of capillary loops (<30 over 5 mm in distal row of nailfold) is associated with an extensive skin involvement and a poor outcome.

LIMITATIONS

The sample size of certain nail diseases in our study was too small and thus further studies with larger population are needed to validate these findings. Use of ultrasound gel application between the contact plate and nail plate was mandatory to enhance and appreciate the colored structures, which could otherwise not be appreciated with dry dermoscopy.

The capillaries of PNF and hyponychium are well appreciated with a dermoscope at 20 to 40× magnifications, ours had only 10× magnification, hence these structures could not be appreciated well.

The polarized Heine's Delta 20 dermoscope doesn't have an inbuilt camera, hence it requires a DSLR camera to be attached with the help of a photo adaptor ring, making the entire arrangement time-consuming and handling of the instrument clumsy. This may affect image quality occasionally.

While examining, the lesion has to be viewed through the scope and this may be difficult to appreciate those with a poor eyesight.

Nail dermoscopy provides new criteria for diagnosis of nail diseases, however, it does not replace histopathology and biopsy should be performed in patients of diagnostic dilemma.

CONCLUSION

Nail dermoscopy, therefore, is a much easier, faster, cost-effective diagnostic procedure that gathers information not visible to the naked eye and may assist in treating the nail ailments at an early stage before permanent dystrophy sets in. However, a good knowledge of nail anatomy and various nail diseases is essential for its interpretation. Dermoscopic nail findings may limit the differential diagnosis without the need for an invasive procedure. It is, therefore, advisable to regularly incorporate nail dermoscopy as a routine examination in every patient.

CLINICAL SIGNIFICANCE

- Dermoscope is beneficial in differentiating between the various causes of onycholysis, e.g., psoriasis, trauma, onychomycosis (DLSO), periungual verruca, etc.
- It helps in differentiating between the nail pits of psoriasis and AA.
- The finding of dilated vessels near the onychodermal band helps in early diagnosis of nail psoriasis.¹³
- It may be used to distinguish between various colors of nail due to blood, melanin, and pseudomonas superinfection.

- It also aids in differentiating between the benign and malignant causes of longitudinal melanonychia and between the pseudo-Hutchinson's and Hutchinson's sign.
- It helps in confirming the origin of nail plate pigmentation in doubtful patients of melanoma/longitudinal melanonychia, and thus contributes in taking a nail matrix biopsy from the appropriate site (proximal/distal) without nail dystrophy.
- In patients of SSc, it helps in effective evaluation of the nailfold capillaries (capillaroscopy),²⁴ which forms one of its diagnostic criteria and correlates with disease severity.
- Nail dermoscopy serves as an effective noninvasive diagnostic procedure for early diagnosis of nail diseases and monitoring their evolution and therapeutic response.

REFERENCES

1. De Berker DAR, Baran R, Dawber RPR. Disorders of nails. In: Burn T, Breathnach S, Cox N, Griffiths C, editors. Rook's textbook of dermatology. 7th ed. Oxford: Blackwell Science; 2004. 4 Vol. p. 62.1- 62.62.
2. Samman PD. The nail in disease. 2nd Ed. London: Heineman W; 1972. p. 1-176.
3. Puri N, Kaur T. A study of nail changes in various dermatosis in Punjab, India. *Our dermatol online*. 2012 July; 3(3):164-170.
4. de Jong EM, Seegers BA, Gulinck MK, Boezeman JB, van de Kerkhof PC. Psoriasis of the nails associated with disability in a large number of patients: results of a recent interview with 1,728 patients. *Dermatology* 1996;193:300-303.
5. Salomon J, Szepietowski JC, Proniewicz A. Psoriatic nails: a prospective clinical study. *J Cutan Med Surg* 2003 Jul-Aug;7(4):317-321.
6. Tan ES, Chong WS, Tey HL. Nail psoriasis: a review. *Am J Clin Dermatol* 2012 Dec 1;13(6):375-388.
7. de Berker D. Management of psoriatic nail disease. *Semin Cutan Med Surg* 2009 Mar;28(1):39-43.
8. Nakamura RC, Costa MC. Dermoscopic findings in the most frequent onychopathies: descriptive analysis of 500 cases. *Int J Dermatol* 2012 Apr;51(4):483-485.
9. Piraccini BM, Bruni F, Starace M. Dermoscopy of non-skin cancer nail disorders. *Dermatol Ther* 2012 Nov;25(6): 594-602.
10. Lencastre A, Lamas A, Sá D, Tosti A. Onychoscopy. *Clinics Dermatol* 2013 Sep-Oct;31(5):587-593.
11. Farias DC, Tosti A, Chiacchio ND, Hirata SH. Dermoscopy in nail psoriasis. *An Bras Dermatol* 2010 Jan-Feb;85(1):101-103.
12. Dogra A, Arora AK. Nail psoriasis: the journey so far. *Indian J Dermatol* 2014 Jul;59(4):319-333.
13. Yadav TA, Khopkar US. Dermoscopy to detect signs of sub-clinical nail involvement in chronic plaque psoriasis: a study of 68 patients. *Indian J Dermatol* 2015 May-Jun;60(3):272-275.
14. Iorizzo M, Dahdah M, Vincenzi C, Tosti A. Videodermoscopy of the hyponychium in nail bed psoriasis. *J Am Acad Dermatol* 2008 Apr;58(4):714-715.
15. Yorulmaz A, Artuz F. A study of dermoscopic features of nail psoriasis. *Adv Dermatol Allergol* 2017 Feb;34(1):28-35.

16. Piraccini BM, Balestri R, Starace M, Rech G. Nail digital dermoscopy (onychoscopy) in the diagnosis of onychomycosis. *J Eur Acad Dermatol Venereol* 2013 Apr;27(4):509–513.
17. De Crignis G, Valgas N, Rezende P, Leverone A, Nakamura R. Dermoscopy of onychomycosis. *Int J Dermatol* 2014 Feb;53(2):e97-e99.
18. Fawcett RS, Linford S, Stulberg DL. Nail abnormalities: clues to systemic disease. *Am Fam Physician*. 2004 Mar 15;69(6):1417-1424.
19. Gordon KA, Vega JM, Tosti A. Trachyonychia: a comprehensive review. *Indian J Dermatol Venereol Leprol* 2011 Nov-Dec;77(6):640-645.
20. Zaias N, The nail in Lichen planus. *Arch Dermatol* 1970 Mar;101(3):264-271.
21. Nakamura R, Broce AA, Palencia DP, Ortiz NI, Leverone A. Dermoscopy of nail lichen planus. *Int J Dermatol* 2013 Jun;52(6):684–687.
22. Braun RP, Baran R, Saurat JH, Thomas L. Surgical pearl: dermoscopy of the free edge of the nail to determine the level of nail plate pigmentation and the location of its probable origin in the proximal or distal nail matrix. *J Am Acad Dermatol* 2006 Sep;55(3):512-513.
23. Ronger S, Touzet S, Ligeron C, Balme B, Viillard AM, Barrut D, Colin C, Thomas L. Dermoscopic examination of nail pigmentation. *Arch dermatol* 2002 Oct;138(10):1327-1333.
24. Dogan S, Akdogan A, Atakan N. Nailfold capillaroscopy in systemic sclerosis: is there any difference between video-capillaroscopy and dermoscopy? *Skin Res Technol* 2013 Nov;19(4):446–449.
25. Ohtsuka T. Dermoscopic detection of nail fold capillary abnormality in patients with systemic sclerosis. *Journal Dermatol* 2012 Apr;39(4):331–335.
26. Beltrán E, Toll A, Pros A, Carbonell J, Pujol RM. Assessment of nailfold capillaroscopy by X 30 digital epiluminescence (dermoscopy) in patients with Raynaud phenomenon. *Br J Dermatol* 2007 May;156(5):892-898.