

Noninvasive Assessment of Donor Area in Patients with Androgenetic Alopecia undergoing Hair Transplantation by Digital Imaging Technique

¹Pavan Raj, ²C Madura, ³BS Chandrashekar

ABSTRACT

Trichoscopic digital imaging is one of the safe, accurate and non invasive method of assessment of donor area for pre transplant evaluation that aids in further plan of action. Our study aimed to calculate the hair density, hair follicular unit density, grouping of hair, average hair per unit, total number hair follicles and follicular units in the safe donor zone. Thorough donor area assessment prior to the hair transplantation is very important to assess the yield of grafts and over all treatment outcome. It is useful in planning the utilization of the grafts for present and future surgeries depending on patient's age and progression of baldness

Keywords: Androgenetic alopecia, Digital imaging technique, Hair transplantation, Safe donor zone.

How to cite this article: Raj P, Madura C, Chandrashekar BS. Noninvasive Assessment of Donor Area in Patients with Androgenetic Alopecia undergoing Hair Transplantation by Digital Imaging Technique. *Int J Dermoscopy* 2017;1(2):50-53.

Source of support: Nil

Conflict of interest: None

INTRODUCTION

Hair transplantation has become increasingly popular in recent years. In addition to medical therapy, more and more number of androgenetic alopecia (AGA) patients are seeking surgical management. There is a need for maximum harvest of grafts without affecting the cosmetic outcome of the donor area in severe grade of baldness. Therefore, thorough assessment of donor area with respect to the hair density, hair follicular unit density, hair grouping, and thickness of hair along with scalp laxity is necessary for a satisfying outcome.

Trichoscopic digital imaging is one of the safest, accurate, and noninvasive methods of assessment of donor area for pretransplant evaluation that aids in further plan of action.¹ There is dearth of literature on the assessment of various parameters in the donor area and hence, this study was taken up to assess the donor area in patients undergoing hair transplantation.

AIMS AND OBJECTIVES

The study aimed to calculate the following parameters in the safe donor zone: Hair density, hair follicular unit density, grouping of hair, average hair per unit, total number hair follicles and follicular units in the safe donor zone, and extent of miniaturization. We also assessed the variation of these parameters in relation to the grade of AGA and age of the patient.

MATERIALS AND METHODS

This was a prospective study conducted for a period of 1 year from January 2016 to December 2016. A total of 30 male patients with AGA seeking hair transplantation were enrolled in the study. Patients who had undergone hair transplantation earlier were excluded from the study.

The safe donor area in the occipital region was marked by identifying the occipital protuberance and the extent of miniaturized hair follicles (ascending and descending hairline). The safe donor area was measured by calculating the area formed by joining the markings. Three spots were marked in the safe donor area: one just above the occipital protuberance and the other two at a distance of 8 cm on either sides of the first point (Fig. 1). The hair length over these areas was trimmed to 1 mm and the digital imaging was done (FotoFinder).

The following parameters were noted in all the patients: Hair follicular units per cm², hair density per cm², hair grouping (1, 2, 3, 4, and >4), average hair per follicular unit, median thickness of hair, density of vellus, and terminal hair (Fig. 2). The observations were tabulated and the average values in all 30 patients were calculated.

^{1,2}Consultant Dermatologist & Dermatosurgeon, ³Chief Dermatologist

¹⁻³Department of Dermatology, Academy of Cutaneous Sciences, Bengaluru, Karnataka, India

Corresponding Author: Madura C, CUTIS Academy of Cutaneous Sciences (CACS), 5/1, 4th main, MRCR Layout Vijayanagar, Bengaluru, Karnataka, India, e-mail: maduradr@gmail.com

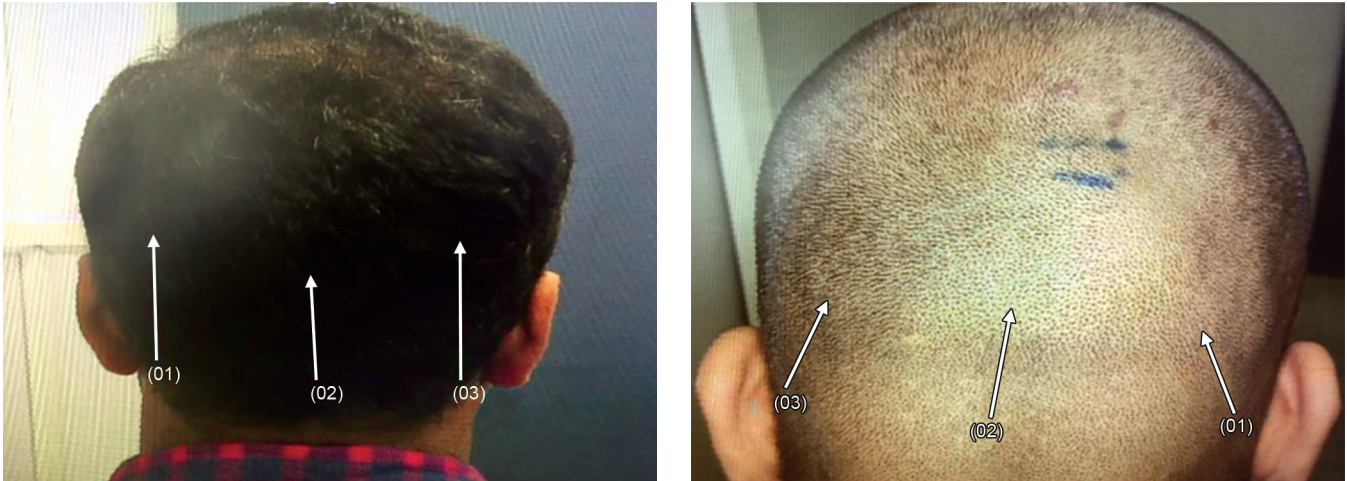

Fig. 1: Prominent markings on the safe donor region, for digital image analysis

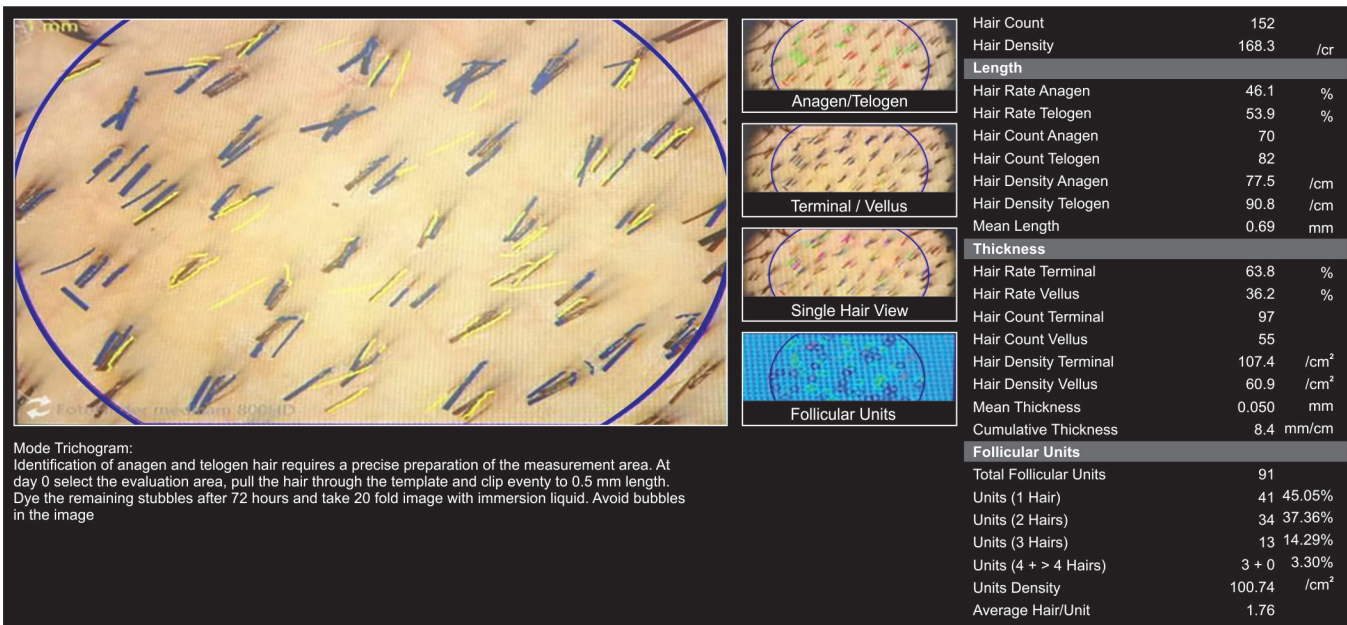


Fig. 2: Trichogram results with various parameters

RESULTS

The AGA ranged from grade III to grade VII according to the modified Norwood–Hamilton classification. Out of the 30 patients, 3 patients (10%) had grade III baldness, 10 had grade IV (33.33%), 9 had grade V (30%), 5 had grade VI (16.66%), 3 had grade VII (10%), and 6 patients (20%) were of variant “a.” The age of the patients from 22 to 44 years, and the mean age was 29.2 years. The average duration of AGA was 6.2 years. The average hair follicular units and density per cm² was 112 and 220 respectively. Grouping of hairs showed maximum number of single hairs (42.26%) followed by 2 hairs (37.53%), 3 hairs (15.5%) and 4/>4 hairs (4.7%). The average hair per unit was 1.83. The average area of safe donor zone was 119.9 cm². The average total number of follicular units was 13,560 and total number of hairs was

26,573 in the safe donor area. The median thickness of hair was 0.056 mm. Density of vellus hair and terminal hair was 56 and 133 per cm² respectively (Table 1).

Follicular units, hair density, and grouping were highest in patients with grade III AGA and those in the age group 31 to 35 years (Tables 2 and 3).

DISCUSSION

Assessment of the donor zone is a prime important step in hair transplantation surgery. The safe donor zone is defined by lack of significant miniaturization. There are approximately 12,500 follicular units in the safe donor zone, out of which 50% of grafts can be safely moved from the donor zone. There can be shrinkage of donor zone by ascending hairline, characterized by miniaturization in the lower margin of the permanent zone at the back of the scalp.

Table 1: Mean results of various parameters

<i>N</i> = 30	Mean
Age	29.2 years
Duration	6.2 years
Donor area/cm ²	119.9
Hair follicular units/cm ²	112.5
Hair density/cm ²	220.5
1 hair	42.3%
2 hairs	37.5%
3 hairs	15.5%
>4 hairs	4.7%
Average hair/unit	1.8
Median thickness (mm)	0.056
Density of vellus hair/cm ²	56.8
Density of terminal hair/cm ²	133.4
Total no of units	13,560
Total no of hairs	26,573

The selection criteria for hair transplantation include the grade of baldness, age of the patient, and rapidity of progression of the baldness. The AGA grades III to V are eligible for hair transplant surgery. Nowadays, there is an increased awareness among the youngsters; hence, the patients with lower grade of AGA are seeking hair transplantation. It is also true that some patients come very late in their advanced grade of baldness. If the donor area is good and the patients accept the results in permissible limits, hair transplantation can be also done in advanced grade of baldness. Studies show that there are 1 lakh hair or 50,000 follicular units on the scalp; among them 12,500 are in occipital region and 6,500 can be safely moved from the occipital safe zone to recipient site. By complete trichoscopic analysis of the donor area in the form of density, grouping, and terminal *vs* vellus hair, we can plan the exact number of grafts that can be safely moved from the donor to the recipient site. There is a significant racial variation in the hair density and follicular unit density among Caucasians, Asians, and

Africans. Africans have a lower hair density (average 160 hairs/cm²) than Asians (average 170 hairs/cm²) and Caucasians (average 200 hairs/cm²).² There are no well-documented studies among Asians or Indians. In a study conducted by Bernstein and Rassman,² the total number of follicular units was 70 to 95/cm². Another study by Jimenez and Ruifernández³ concluded that the follicular unit density was between 65 and 85 units/cm² and the hair density was between 120 and 200 hairs/cm². Limmer⁴ found a range of 120 to 240 hairs/cm² and Haber⁵ 144 to 176 hairs/cm². The majority of the hair emerges as 2-hair follicular units. The second most common unit is the 3-hair unit. The density and grouping in Asians are less compared with the Caucasians. In our study, we measured the safe donor zone and calculated the donor area, which varied among the patients and with size of the scalp. Our study shows average total number of follicular units as 13,560 and total number of hairs as 26,573 in the safe donor area, and it correlated with previous studies. Density and grouping are genetically determined. We also observed the density and grouping to be less on the sides compared with the center of safe donor zone. We observed age-related changes in donor zone like shrinkage of donor zone with decreased number of follicular grafts and increased single follicular units with increased aging; however, there was no change in hair thickness (Table 1). There was decrease in hair follicular unit density, hair density, and median thickness of hair with advancing baldness (Table 2). The anagen to telogen ratio and terminal to vellus ratio varied with progressive rate of baldness and also the type of baldness (anterior pattern/diffuse pattern). We observed some of the scalp changes like shrinkage of donor zone by ascending hairline and also diffuse thinning of the donor zone (diffuse unpatterned AGA), which requires further studies and evaluation.⁶ The dermoscopic evaluation proves valuable in the

Table 2: Variation of parameters according to the age of the patients

Age group (years)	Donor area/cm ²	Hair follicular units/cm ²	Hair density/cm ²	1 hair %	2 hairs %	3 hairs %	4/>4 hairs %	Average hair/unit	Median thickness (mm)	Total no of units	Total no of hairs
<25	130	110	216	42	38	15	5	1.82	0.054	14577	28348
26 to 30	119	111	217	42	37	15	5	1.82	0.055	13297	26076
31 to 35	115	116	234	40	37	16	5	1.87	0.058	13379	26994
>35	111	115	206	50	33	14	4	1.7	0.055	13106	23503

Table 3: Variation of parameters according to the grade of AGA

Grades of AGA	Donor area/cm ²	Hair follicular units/cm ²	Hair density/cm ²	1 hair %	2 hairs %	3 hairs %	4/>4 hairs %	Average hair/unit	Median thickness (mm)	Total no of units	Total no of hairs
Grade III	137	117	237	4	39	15	5	1.83	0.062	16107	32729
Grade IV	131	110	215	41	38	15	5	1.84	0.056	14578	28514
Grade V	111	116	227	43	36	16	5	1.84	0.054	12890	25384
Grade VI	106	110	216	42	38	16	4	1.82	0.058	12008	23440
Grade VII	111	108	203	43	37	12	6	1.76	0.052	12211	22737

selection of patients for hair transplantation, documenting hair growth, and analyzing esthetic complications.⁷

CONCLUSION

The main advantages of pretransplant dermoscopic assessment are to calculate the total donor grafts, to plan the sessions depending on progression and grade of baldness, and lastly to help choose the technique of harvest. If follicular unit extraction (FUE) is done in the first session, there may be difficulty in harvesting grafts in the second session of FUE or follicular unit transplantation may not be possible as there are already reduced grafts in the area. If we know the number of grafts in the donor zone and area of good grouping, sessions of surgery can be planned depending on the grade and progression of baldness. In a young patient with grade III AGA, who requires only 1500 to 1800 grafts, planning can be done to harvest so many grafts without affecting the quality of the donor zone, by leaving safe zone for future harvest. This is the first kind of study that assesses the various above-discussed parameters of the donor zone with respect to age and advancing baldness.

We conclude that a thorough donor area assessment prior to hair transplantation is mandatory to assess the

yield of grafts and overall treatment outcome. It is useful in planning the utilization of the grafts for present and future surgeries depending on patient's age and grade of baldness.

REFERENCES

1. Jain N, Doshi B, Khopkar U. Trichoscopy in alopecias: diagnosis simplified. *Int J Trichology* 2013 Oct-Dec;5(4):170-178.
2. Bernstein RM, Rassman WR. The logic of follicular unit transplantation. *Dermatol Clin* 1999 Apr;17(2):277-295.
3. Jimenez F, Ruifernández JM. Distribution of human hair in follicular units. A mathematical model for estimating the donor size in follicular unit transplantation. *Dermatol Surg* 1999 Apr;25(4):294-298.
4. Limmer BL. The density issue in hair transplantation. *Dermatol Surg* 1997 Sep;23(9):747-750.
5. Haber RS, Stough DB. Accurate estimation of graft requirements when using multibladed knives. In: Stough DB, Haber RS, eds. *Hair replacement: surgical and medical*. St. Louis: Mosby-Year Book, Inc. 1996:138-142.
6. De Lacharrière O, Deloche C, Misciali C, Piraccini BM, Vincenzi C, Bastien P, Tardy I, Bernard BA, Tosti A. Hair diameter diversity: a clinical sign reflecting the follicle miniaturization. *Arch Dermatol* 2001 May;137(5):641-646.
7. Madura C, Ravipati N, Chandrashekar BS. Clinical and trichoscopic correlation of scalp in patients who had undergone hair transplantation. *Int J Dermascopy* 2017 May-Aug;1(1):20-25.